



Case Study

EFFECT OF APAMARGA PRATISARANIYA TEEKSHNA KSHARA IN THIRD DEGREE INTERNAL HAEMORRHOIDS

Sirajudheen V E^{1*}, K Gangadharan², Sreelekha MP³

*1PG Scholar, ²Professor and HOD, ³Associate Professor, Department of Shalyatantra, Government Ayurveda College, Kannur, Kerala, India.

Article info

Article History:

Received: 15-12-2024

Accepted: 17-01-2025

Published: 07-02-2025

KEYWORDS:

Apamarga
Pratisaraniya
Teekshna Kshara,
Arshas, Third
Degree Internal
Haemorrhoids.

ABSTRACT

Haemorrhoids are defined as the dilated veins within anal canal in the sub epithelial region formed by radicles of superior, middle and inferior rectal veins. Based on the degree of prolapse, they are classified into 1st, 2nd, 3rd, and 4th degree haemorrhoids. According to Ayurvedic classics, it can be correlated with *Arshas*; the muscular sprouts torture the person in the same way that enemies do. *Acharya Susruta* mentioned four therapeutic measures such as *Bheshhaja*, *Kshara*, *Agni* and *Sastra karma* in the management of *Arshas*. Ligation and excision, Laser therapy, Sub mucosal haemorrhoidectomy are the commonly done procedure in the management of third-degree haemorrhoids. But these are often associated with post operative complications like Pain, Secondary haemorrhage, Urinary retention, Bowel incontinence and Recurrence. *Kshara Karma* is a proven para-surgical procedure for the management of *Arshas*. It is minimally invasive, cost effective, requires less hospital stay and having less complications. In the present study, *Apamarga Pratisaraniya Teekshna Kshara* was applied in a third-degree internal haemorrhoids. The assessment was done as per the subjective and objective criteria and anal speculum examinations, daily up to one week and follow up done on 15th and 30th days. It was found that *Apamarga Pratisaraniya Teekshna Kshara* is effective in the management of third-degree internal haemorrhoids. Symptoms like bleeding per rectum, prolapse of the mass, and pain got significantly reduced on 30th day. From this study, it can be concluded that, *Apamarga Pratisaraniya Kshara Karma* is an effective treatment in the management of third-degree internal haemorrhoid.


INTRODUCTION

Haemorrhoid is one of the commonest diseases of the anorectal region, having a high prevalence rate among all anorectal disorders. Haemorrhoids are dilated veins within the anal canal in the subepithelial region formed by radicles of superior, middle, and inferior rectal veins.^[1] It is the downward sliding of anal cushions abnormally due to straining or other causes. It is commonly termed a pile, which is derived from the Latin word *pila*, meaning ball. The pile mass generally arises at 3, 7, and 11 o'clock positions ^[2]. Clinical features in general include bright red-coloured bleeding during defecation (splash in the pan),

prolapse, pain, mucous discharge, and anaemia^[3]. Based on the degree of prolapse, they are classified into 1st, 2nd, 3rd, and 4th degree haemorrhoids. In third degree, there is prolapse during defecation but it does not returns back spontaneously and need digital repositioning^[4].

According to Ayurvedic classics, it can be correlated with *Arshas*; the muscular sprouts torture the person in the same way that enemies do. Additionally torture the person by preventing the rectum from passing through. It is enlisted in "*Ashtamahagadas*," eight diseases that are challenging to treat. The condition is classified as *Maharogas* because it affects the *Marma* and is also known as *Deerghakaalanubandhi*, so it is *Duschikitsya* i.e., - difficult to treat.

Ligation and excision, Laser therapy, Sub mucosal haemorrhoidectomy are the common surgical procedures practiced in the management of third-degree haemorrhoids. Some patients may be unfit for

Access this article online	
Quick Response Code	
	https://doi.org/10.47070/ijapr.v13i1.3549
Published by Mahadev Publications (Regd.) publication licensed under a Creative Commons Attribution-NonCommercial-ShareAlike 4.0 International (CC BY-NC-SA 4.0)	

surgery and all these procedures have merits and demerits with limitations. There may be many complications after the procedure, which include severe pain due to spasm, ulceration, urinary retention, secondary haemorrhage, anal stricture, recurrence, and incontinence^[5].

In Ayurveda, *Susruta* mentioned *Chatur Vidha Sadanopaya* for the management of *Arshas*. They are *Bheshaja Chikitsa* (medical management), *Kshara Chikitsa* (alkaline management), *Agni Chikitsa* (thermal cauterization), and *Sastra Chikitsa* (surgical management)^[6] Among these procedures, *Kshara chikitsa* or *Kshara Karma* is indicated in those haemorrhoids, which are *Mrdu* (soft), *Prasruta* (spread), *Avagaḍha* (deep), and *Ucchrita* (projected). *Kshara* is considered superior among the *Sastras* and *Anuśastras*.^[7] The effect of *Apamarga Pratisaraniya teekshna Kshara* in the treatment second degree haemorrhoid is already studied and it is found that, *Apamarga Pratisaraniya Kshara Karma* is effective in the management of second-degree haemorrhoids. The present study aims to evaluate the effect of *Apamarga Pratisaraniya Teekshna Kshara* in Third degree internal haemorrhoids.

Patient Information

Presenting Concerns

A 24-year-old male patient came to Anorectal OP of Shalyatantra Department, Government Ayurveda college Kannur, with complaints of prolapse of mass during defecation associated with bleeding for the last

2 years. The mass was reduced by him digitally after defecation. The bleeding was few drops in amount and there were no complaints of pain, mucous discharge and pruritus ani. There were no relevant co-morbidities reported. Detailed Physical and local examination was done along with laboratory investigations.

Clinical Findings

Physical Examination: BP-118/76mm of Hg, PR-70/Min

Temp-97°F, R.R-16/min

Anorectal Examination

Inspection- No abnormality detected

On straining- A reddish purple coloured mass was protruded out.

Digital rectal examination

Normotonic sphincter, no spasm and not felt any irregularities on the wall.

No blood stained mucous seen on the tip of index finger.

No abnormality detected in the lumen and wall of anal canal.

Proctoscopy examination

Lumen- A large third-degree haemorrhoid mass with multiple bleeding points was seen, which was prolapsed out after proctoscopy examination.

Colour of mucosa- Reddish purple colour

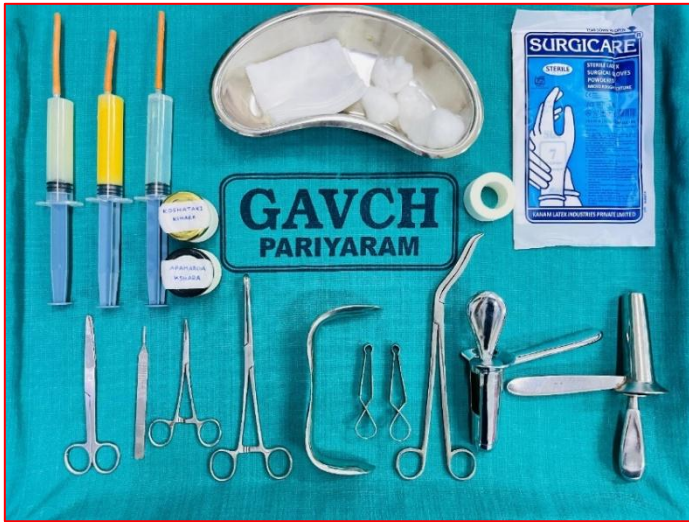Diagnosis- Third degree internal haemorrhoid

Pre -Operative Investigation

Hematology		Biochemistry	
Haemoglobin	16 gm%	FBS	101 mg%
Total count	5370cells/cumm	Triglycerides	154 mg%
ESR	9 mm/hr	Creatinine	1.2 mg%
B.T	1.4 min	Bilirubin (Total)	1.1 mg%
C.T	4.3 min	SGPT	48 IU/L
Platelet	3.40000/microlitre	SGOT	35 IU/L
Serological Test		Urine Analysis	
HIV	Negative	Albumin	Nil
VDRL	Negative	Sugar	Nil
HBs Ag	Negative	Pus cells	1-3/HPF

Therapeutic Intervention- Pratisaraniya Kshara Karma

Figure 1: Materials Required for Kshara Karma



1. Examination table
2. Shadowless light
3. Instruments: Artery forceps, scissors, normal proctoscope, Sim’s speculum, *Salaka*,
4. Surgical glove
5. Sterile cotton
6. Kidney tray
7. Sterile cotton pad
8. Sterile water
9. Micropore
10. Stop watch
11. *Apamarga Kshara*
12. *Yashtimadhu Grita*
13. *Nimbu Swarasa*
14. 20ml syringes

**Kshara Karma Procedure
Pre-Operative Procedures**

Prior to procedure, the participant was advised to remain nil orally for at least 4 hours. Written consent was taken prior to the procedure, the part preparation was done, and enema was given in the early morning.

Operative Procedures

The patient was made to lie in lithotomy position on the operation table. The anal and perianal areas were cleaned with antiseptic solution. After proper anal dilatation, normal proctoscope was introduced into the anal canal and mass was visualized properly and the position of mass was located, then Sims anal speculum was introduced and gently retracted so that the mass was visible completely for the procedure. Then the pile mass was cleaned with a cotton swab, and the surrounding healthy anal mucosa got covered with cotton to prevent spilling of *Kshara* on it. Then *Apamarga Kshara* was applied over the pile mass with the help of *Shalaka*, and the area was closed with palm till the pile mass turned a purple-black colour (*Pakwa Jambu Phala Varna*). After this procedure, the anal canal was washed with *Nimbu Swarasa* and wiped well. This was done to neutralize the pH and to remove all the remaining *Kshara*. Then the area is cleaned with sterile water. Then ghee prepared with *Yashti Madhu* got smeared over the area to prevent burning sensation, and local oedema. Thereafter the anal canal was packed with gauze pads, and the patient was shifted to the postoperative ward for observation.

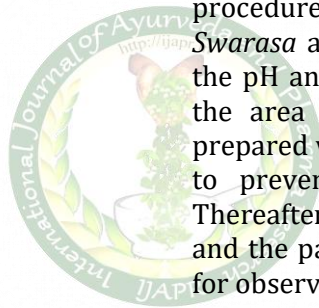


Table 1: Post Operative Procedure

Medication	Dosage and Duration
<i>Guggulu Thikthakam Kashayam</i>	15ml + 45ml lukewarm water twice daily before food
<i>Triphala Choornam</i>	One teaspoon at night for 1 week
<i>Guggulupanchapala Churna</i>	5gm with hot water two times daily for 2 weeks
Sitz bath with lukewarm water	15 minutes two times daily for 2 weeks
<i>Yasti Ghrita</i> instillation	10ml in to anal canal twice daily for First 3 days
<i>Murivenna</i> Instillation	10ml in to the anal canal twice daily- From third day onwards to 30 days

Assessment Period

Patient was assessed daily up to one week by using an assessment chart. Follow-up was taken on the 15th and 30th days after the procedure. During the visit, patient was assessed on clinical features listed in the assessment criteria and also examined clinically.

Assessment Parameters

Table 2: Subjective Parameters

Pain (VAS Scale)	
Grade	Explanation
0	No pain
1	Mild pain (1-3)
2	Moderate pain (4-7)
3	Severe pain (8-10)
Bleeding Per Rectum	
0	No bleeding
1	0-5 drops
2	6-10 drops
3	Bleeding in the form of a splash in the pan

Table 3: Objective Parameters

Size of Pile Mass Grading	
Grade	Size of pile mass
0	No protrusion of mass
1	Bleeding with no protrusion of mass (First degree)
2	Bleeding along with protrusion during defecation, which is spontaneously reduced after defecation (Second degree)
3	Bleeding and protrusion which need digital repositioning (Third-degree)

Proctoscopy Examination

Table 4: Visible mass in Proctoscopy

Grade	Visible Mass
0	No mass seen
1	First degree mass
2	Second degree mass
3	Third degree mass

RESULT

Figure 2: Before procedure

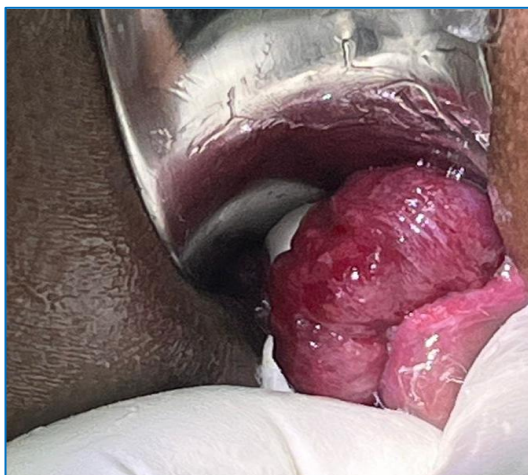

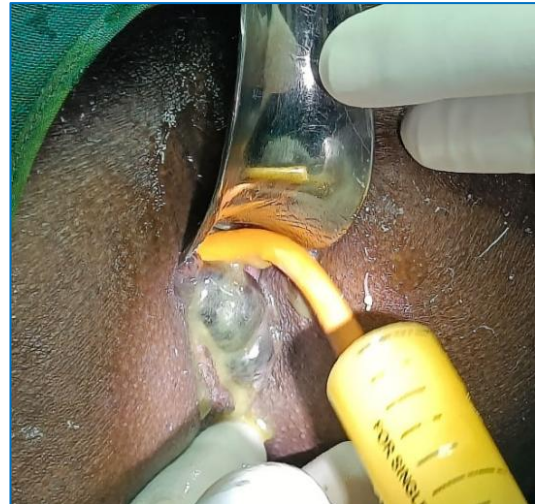
Figure 3: After Application of Kshara



Figure 4 : Pakwa Jambu Phala Varna

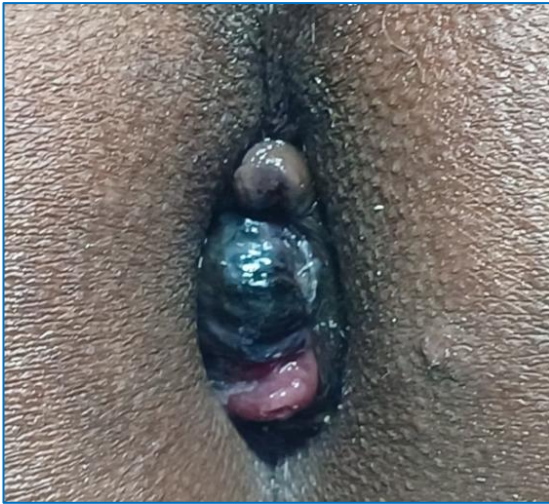

Figure 5: Application of Yaste Ghritha



Post Operative Findings

Figure 6: Speculum examination-4 th Day

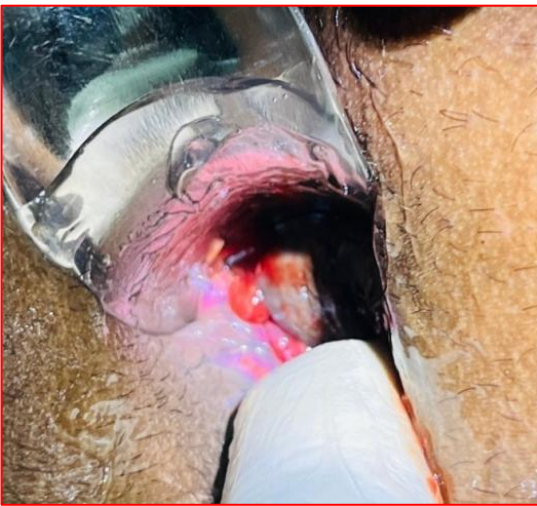

Figure 7: Speculum examination-7 th Day

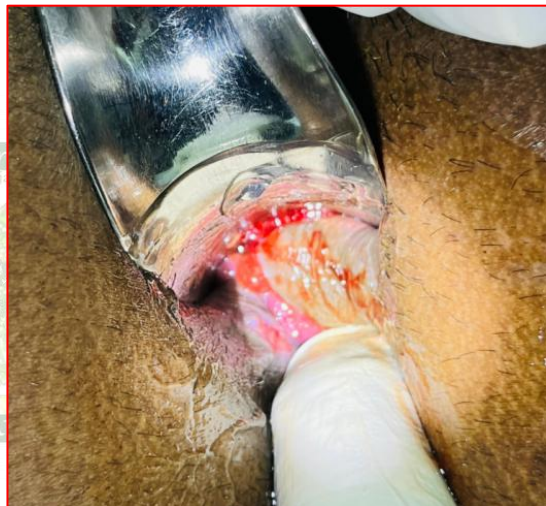

Figure 8: Speculum examination-15 th Day

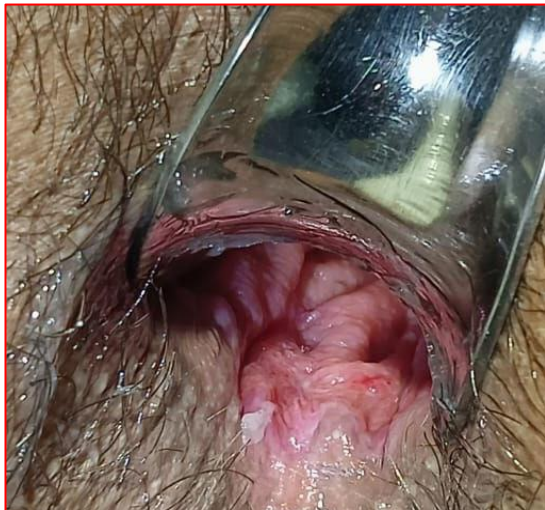

Figure 9: Speculum examination- 30 th Day

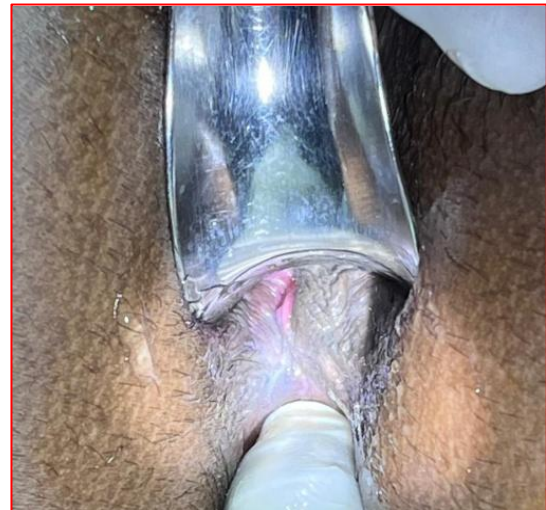

Table 5: Assessment Score

Parameters	Score before the treatment		Score after the treatment		
	Day 0	Day 7	Day 15	Day 30	
Bleeding	2	0	0	0	
Pain	0	1	0	0	
Prolapse	3	0	0	0	
Proctoscopy	3	Not done	0	0	

Analysis of Result

Graph 1- Effect of Kshara Karma

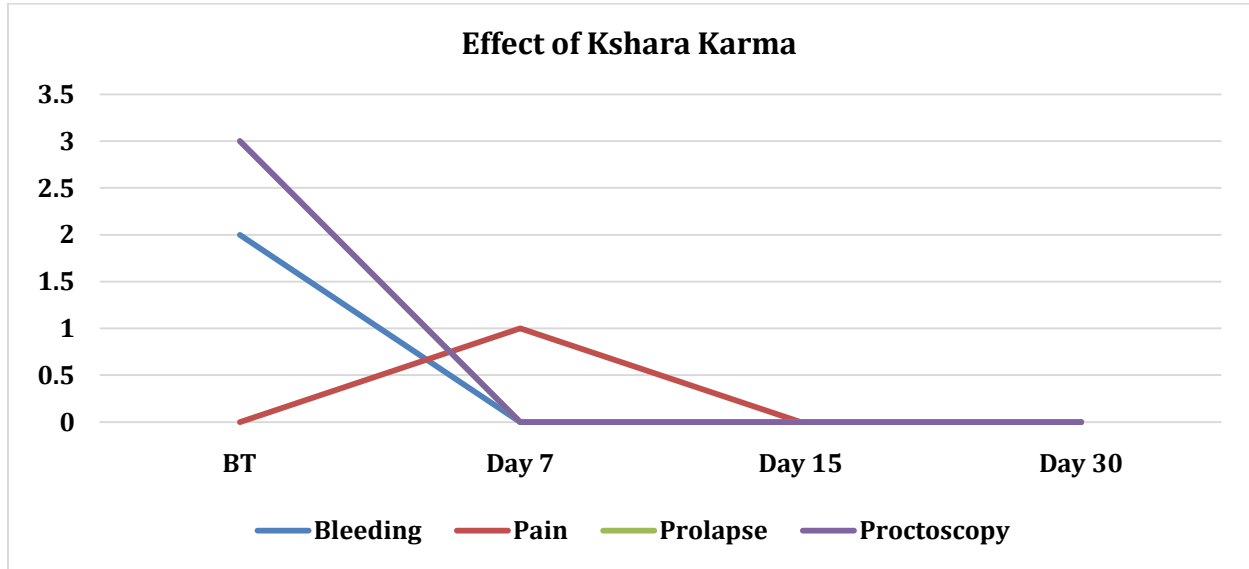


Table 6: Mode of Action of Kshara on Haemorrhoid Mass

S.No.	Therapeutic Action	Properties of Kshara
1	Stage of necrosis of the pile mass	Due to <i>Ushna</i> , <i>Teekshna</i> and <i>Pachana</i> property
2	Stage of sloughing of necrosed tissue	Due to <i>Chedana</i> , <i>Bhedana</i> and <i>Lekhana</i> property
3	Stage of wound healing	Due to <i>Shodana</i> and <i>Ropana</i> property

DISCUSSION

The procedure was economical and required minimal hospitalization, so it was greatly accepted by the patient. The time to become *Pakwa Jambu Varna* (blackish discolouration) was 40 seconds which indicates the *Tikshna* property of *Apamarga Kshara*. After the assessment period of 30 days, it was found that symptoms like bleeding, post-operative pain and protrusion, was relieved completely. *Kshara Karma* made cauterization of pile mass due to its high alkaline nature, and on application it turns the colour of the mass to *Pakwajambu Phala Varna* (blackish discolouration), which is the ideal feature of cauterization of hemorrhoidal mass (*Samyag Dagdha Lakshana*). It is due to the necrosis of pile mass. Here, both coagulative necrosis and ischemic necrosis of hemorrhoidal mass occur, and the mass gets sloughed off within 7 days., There was mild postoperative burning pain in the initial 5 days, which was managed by instillation of *Yasti Madhu Ghrita* and internal medications. After *Kshara Karma*, it was observed that,

the purple or pinkish coloured anal mucosa was turned to a red colour on 15th day, it may be due to the presence of red granulation tissue over the ulceration and in the 3rd and 4th weeks it got changed to a white colour due to the fibrosis of the ulceration. *Kshara Karma* made complete regression of haemorrhoid mass and the ulceration healed completely within 30 days restoring the healthy tissue with minimal scar formation.

It was found that, *Kshara Karma* made complete regression of pile mass. Due to *Pachana Guna* of *Kshara*, the mass got coagulated and necrosed. By the *Ksharana* and *Kshanana* property the necrosed mass got destructed and displaced. By the combined effect of *Chedana*, *Bhedana*, and *Lekhana* properties, the necrosed pile mass sloughed off and disappeared completely. On the 30th day, it was observed that, the ulceration over the mucosa was completely healed and patient was free from haemorrhoid symptoms. All these findings collectively show that, *Apamarga*

Pratisaraniya Teekshna Kshara Karma is effective in the management of third-degree internal haemorrhoids.

CONCLUSION

- It is found that *Apamarga Pratisaraniya Teekshna Kshara Karma* was effective in the management of third-degree internal haemorrhoids.
- *Kshara Karma* made cauterization of pile mass due to its high alkaline nature, and on application it turns the colour of the mass to *Pakwajambu Phala Varna*.
- Both coagulative necrosis and ischemic necrosis of hemorrhoidal mass occur, and the mass gets sloughed off within 7 days.
- After the *Kshara Karma* therapy, symptoms like bleeding per rectum, prolapse of the mass were relieved completely.
- *Kshara Karma* made complete destruction of haemorrhoid mass and the ulceration healed completely within 30 days with minimal scar formation.
- Finally, it can be concluded that *Apamarga Pratisaraniya Teekshna Kshara* can be used as an effective drug in the management of third-degree internal haemorrhoids.

Patient Perspective

- The patient had been experiencing haemorrhoid symptoms for the last 2 years. On 15th day after the treatment, there was no prolapse and bleeding and he was completely relieved the symptoms of haemorrhoid.
- Patients withstood the procedure well.

- During the procedure and assessment period there were no unwanted effects or complications were reported.

Acknowledgement

We express our sincere gratitude to Dr. Manju P and Dr. Namitha TP, Assistant professors, Department of Shalyatantra, Govt. Ayurveda College, Kannur. We also extend our appreciation to the post graduate scholars, House surgeons, Nursing staff, for their valuable support in managing this case.

REFERENCES

1. Sriram Bhat, SRB's Manual of Surgery, Ed Fourth, Chapter 25th, Jaypee Brothers Medical Publishers, 2013, Pg No 969
2. Sunil Chumber, Essentials of Surgery Ed First, Chapter 46th, Jaypee Brothers Medical Publishers, 2005, Pg No 872
3. Somen Das, A Concise Textbook of Surgery, Ed 9th, chap 45th, Published by Dr. S. Das, Kolkata, Pg No 1076-1077
4. Courteny M.Towndend Jr, R.Daniel Beauchamp, B. Mark Evers, Kenneth L. Mattox, Sabiston Text Book of Surgery, Ed First South Asian, Vol 2, Chapter 52, Thomson Pres India Ltd 2017, Pg No 1400
5. Sriram Bhat, SRB's manual of surgery, Ed Fourth, Chapter 25th, Jaypee Brothers Medical Publishers, 2013, Pg No 1047
6. Prof. K.R. Srikanta Murthy, Susrutha Samhita, Ed Reprint, vol 2 Chikita Sthana, chap 6th Chaukhamba Orientalia, Varanasi 2016, Pg No 77
7. Prof Dr.Vasant C. Patil, Dr.Rajeswari. NM, Susruta Samhita, Ed First Vol 1, Sutrasthana Chapter 11, Chaukhamba Publication 2018, Pg No 129

Cite this article as:

Sirajudheen V E, K Gangadharan, Sreelekha MP. Effect of Apamarga Pratisaraniya Teekshna Kshara in Third Degree Internal Haemorrhoids. International Journal of Ayurveda and Pharma Research. 2025;13(1):1-7.

<https://doi.org/10.47070/ijapr.v13i1.3549>

Source of support: Nil, Conflict of interest: None Declared

*Address for correspondence

Dr. Sirajudheen V E

PG Scholar,

Department of Shalyatantra,

Government Ayurveda College,

Kannur, Kerala.

Email: siraj.eranjoly@gmail.com

Disclaimer: IJAPR is solely owned by Mahadev Publications - dedicated to publish quality research, while every effort has been taken to verify the accuracy of the content published in our Journal. IJAPR cannot accept any responsibility or liability for the articles content which are published. The views expressed in articles by our contributing authors are not necessarily those of IJAPR editor or editorial board members.