



Case Study

MANAGEMENT OF TRAUMATIC PERFORATION OF TYMPANIC MEMBRANE THROUGH AYURVEDA

Pahwa Preeti^{1*}, Saini Jasmeen², Vinaik Ashu³

^{*1}Associate Professor, ²PG Scholar, PG Department of Shalakyta-Tantra, Patanjali Bhartiya Ayurvedigyan Evam Anusandhan Sansthan, Haridwar, Uttarakhand.

³Professor, PG Department of Shalakyta-Tantra, Shri Krishna Ayush University, Haryana, India.

Article info

Article History:

Received: 29-04-2024

Accepted: 26-05-2024

Published: 10-06-2024

KEYWORDS:

Traumatic perforation, Ayurveda, *Sarivadi Vati*, *Lakshadi Guggul*, *Gandha Taila*, *Mahayograj Guggul*.

ABSTRACT

Traumatic tympanic perforations can occur due to various reasons, such as concussion, insertion of objects, temporal bone fractures, barotrauma, etc. Slap injuries are a common cause. Symptoms include sudden conductive deafness, pain and/or blood-stained discharge. Tinnitus and vertigo may complicate the condition. Appropriate and timely management is crucial to reduce the risk of permanent impairment, as studies indicate that spontaneous healing occurs within 1.5 to 3 months. While Ayurvedic texts don't directly mention traumatic tympanic perforations, they can be categorized as '*Agantuja Vrana*' (wounds caused by external factors). Ayurvedic treatment includes both local and systemic approaches. In this case study, medicines were used internally for 2 months: *Sarivadi Vati*, *Lakshadi Guggul*, *Mahayograj Guggul*, *Gandha Taila* capsules and a combination of *Vatashamaka Churnas*. This combination led to significant improvement; the perforation completely healed in 2 months. Thus, internal use of these drugs helped in the healing of traumatic perforations.

INTRODUCTION

The tympanic membrane is a delicate, translucent membrane separating external ear and middle ear. This membrane helps in conduction of sound through increasing sound pressure by hydraulic action by about 14 times. Anatomically, it is a part of external ear and functionally, it is a part of middle ear. It can be perforated due to various reasons. Apart from middle ear infections, tympanic membrane can be perforated due to penetration injuries, temporal bone fractures or pressure wave injuries (caused by air or fluid). Slap injuries accounting to barotrauma caused by air pressure changes are more common among them. Among traumas, about 50% are attributable to slap injuries or direct blows. Other reasons may be self-inflicted penetrating injuries account for about 25%, with 25% being due to causes that include diving and aviation barotrauma, foreign bodies such as button batteries, other caustic substances, insects, welding

debris, and blast injuries^[1]. Symptoms include sudden conductive deafness, pain and/or blood-stained discharge. Tinnitus and vertigo may complicate the condition. The perforation also increases the risk of otitis media. In modern science, it has been mentioned that spontaneous healing rates are good, but with increasing age and perforation size, and middle ear infection the healing becomes slower. Large studies indicate that spontaneous healing occurs within 1.5 to 3 months. The non-healing perforations need surgeries i.e., myringoplasty and tympanoplasty.

In Ayurvedic texts, *Nidana* of *Karna Roga* (ear diseases) has been mentioned in detail. One among them is *Mithyayoga* of *Shastra* (improper use of instrument). It can lead to trauma in the ear. This trauma may result in injury to either the wall of the external auditory canal (EAC) or perforation of the tympanic membrane. Based on the *Nidana*, it can be categorized as *Agantuja Vrana* (wound caused by external factors). These wounds result from external causes, such as trauma, chemical exposure, insect bites or other external agents^[2].

After the trauma, the repair process starts which is thought to be controlled by the epithelial layer. After 48 hours, the epithelial hypertrophy starts

Access this article online	
Quick Response Code	
	https://doi.org/10.47070/ijapr.v12i5.3218
Published by Mahadev Publications (Regd.) publication licensed under a Creative Commons Attribution-NonCommercial-ShareAlike 4.0 International (CC BY-NC-SA 4.0)	

and the edges of the TM begin to close, and then these are followed by the development of the fibrous component of the lamina propria. The closure rate of the perforation is affected by many factors. The two main factors that affect the recovery of the perforation are the size of the perforation and the secondary developed infections. The small perforations have better closure rates and close earlier as expected^[3].

Here in this case study, *Sarivadi Vati*, *Lakshadi Guggul* and *Mahayograj Guggul*, *Gandha Taila* mentioned in Various Ayurvedic texts and *Churna* combinations including *Mulethi*, *Ashwagandha* and *Vatari Churna* was used for their *Shotha-hara*, *Ropana*, *Vata-shamaka* and *Dhatu-poshaka* properties. This treatment follows the approach of *Sanshamana Chikitsa*.

Available modalities for traumatic perforation vary in safety, affordability and efficacy. Not all the patients respond equally to these treatments. Thus, continuous research is necessary to find effective combinations of treatment for managing this condition.

MATERIALS AND METHODS

Case Study

A 38-years-old female patient visited the Out Patient Department (OPD) of Shalakyatantra Department of Patanjali Ayurved Hospital, Haridwar, Uttarakhand, with the complaint of air leakage from right ear when she filled air in mouth. She gave the history of being slapped on the right ear by her 4-years-old son 1 month ago. She was not being diagnosed for any type of ear disease prior to this accident. After the accident, she had itching in right ear

and air leakage on filling air in the mouth. For that she went to Government Multi-specialty Hospital, Sector-16, Chandigarh. There a big central perforation with no discharge was noted in the right ear tympanic membrane. Left ear was recorded normal. She was given Ciprofloxacin ear drops for instillation in the right ear for 1 week along with precautions to keep the ear dry and was advised to seek surgical intervention PTA was done 1 month ago which read mild conductive hearing loss (28dB) in right ear. Left ear audiometry was normal.

After the prescribed measures, she wasn't relieved of the symptoms. On clinical examination, there was no swelling in pinna, pre-auricular and post-auricular areas in both ears. On otoscopy, in right ear tympanic membrane there was a big central perforation with no discharge, ear canal was normal. Left ear canal and tympanic membrane was normal. (see figure 1)




Figure 1: Right TM showing single central perforation and intact left TM

Therapeutic Intervention and its Duration

After observing all the clinical features, following medicines were given to the patient for 2 months: (see table 1)

Table 1: Therapeutic intervention, their dose, Anupana and duration

Sr.No.	Yoga	Dose	Anupana	Duration
1.	<i>Sarivadi Vati</i>	250mg twice a day after food	Lukewarm water	2 months
2.	<i>Lakshadi Guggul</i>	1000mg twice a day after food	Lukewarm water	2 months
3.	<i>Mahayograj Guggul</i>	300mg twice a day after food	Lukewarm water	2 months
4.	<i>Gandha Taila</i> (Capsules)	1 capsule (300mg) twice a day	Lukewarm water	2 months
5.	Combination of: <i>Ashwagandha Churna</i> 100gm <i>Vatari Churna</i> 100gm <i>Mulethi Churna</i> 50gm	All of them were mixed and 5gm twice a day after food	Lukewarm water	2 months

OBSERVATIONS AND RESULT

The case was evaluated after 2 months of *Sanshamana Chikitsa*. Significant relief was observed in the feeling of air leakage and itching within 1 month and complete perforation was healed in 2 months. Research suggests that the prognosis is better if the patient is young and perforation is new. Here the patient was in middle age. Studies suggest that the outcome is significantly good if medical management is commenced within 3 or 4 days after the perforation^[4].

In the current study, the patients showed significant changes, improving from perforation to healed perforation but it took 2 months as the patient visited for the treatment after 1 month of trauma (see figure 2 and 3). During the treatment, the patient diligently refrained from inserting her finger or any other object into the ear canal. Dry ear canal precautions were taken. These precautionary measures were essential to prevent further harm to the already compromised

tympanic membrane (eardrum). Adhering to these guidelines contributes significantly to the healing process and overall recovery. During the entire study period and follow-up, no adverse reactions were

reported by the patients. This positive outcome indicates the safety and well-tolerated nature of the treatment.

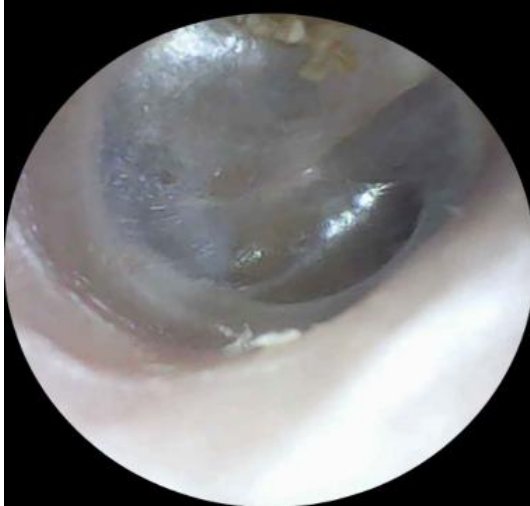

Figure 2: Right ear healed perforation

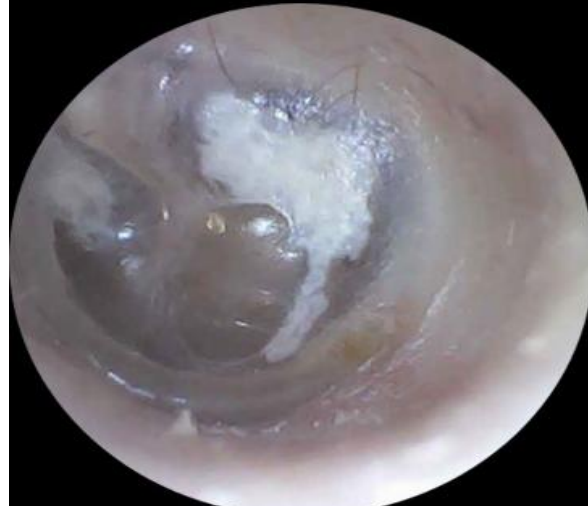

Figure 3: Left ear intact TM with TS patch

DISCUSSION

Studies have reported that at least 85% of TTMP close spontaneously and heal without any active intervention within 3 to 4 weeks of injury. Animal studies have demonstrated that perforations heal by means of epithelial migration which starts from the outer epithelial layer, with later healing of the lamina propria and the mucosal layer. The epithelial generation centre is located near the annulus and the handle of the malleus.

The approach we took to manage traumatic tympanic membrane perforations was conservative. It involved inactive intervention allowing for spontaneous closure. We avoided any packing or dressing within the ear canal. This allowed the natural healing process to occur without interference. We emphasized strict hygiene and infection control. Preventing infection was crucial for successful healing. We administered systemic *Dravyas* with *Shotha-hara*, *Ropana*, *Vata-shamaka* and *Dhatu-poshaka* properties. We followed the approach of *Sanshamana Chikitsa* for *Agantuja Vrana*. Here, *Rakta dosha* vitiation along with *Tridosha Prakopa* is being considered in related ear. This conservative approach aims to promote natural healing while minimizing unnecessary interventions. Consultation with a healthcare professional is essential for personalized management based on individual circumstances.

The treatment was given for 2 months. After that, patient was re-evaluated and outcome of treatment was noted.

Mode of Action of Drugs

Sarivadi Vati^[6]

It is a reference from *Bhaisajya Ratnavali*. The drug is specifically mentioned for *Karna Rogas* under *Vati* preparations. The contents include: *Sariva*,

Mulethi, *Kushtha*, *Tvak*, *Ela*, *Tejapatra*, *Nagakesara*, *Priyangu*, *Neelotpala*, *Giloy*, *Lavanga*, *Haritaki*, *Vibhitaki*, *Amalaki*, *Abhraka Bhasma* and *Loha Bhasma*. So probable mode of action of *Sarivadi Vati* can be said as all the contents are having mainly *Madhura* (sweet), *Kashaya* (astringent) and *Tikta* (bitter) *rasa* and *Laghu* (easily digestible and causes lightness in the body) and *Ushna* (heat) *Guna*. Therefore, it acts as *Kleda-shoshaka* (absorbs putrefaction) and *Vrana-shodhaka* (wound purifier).

Sariva acts as *Rakta-stambhak* (haemostatic), *Kushtha* as *Lekhana* (scrapping) and *Kandu-hara*, *Giloy* as *Rasayana* (rejuvenator) and *Krimi-hara* (anti-microbial), *Mulethi* as *Uttama Ropana* (best for wound healing), *Rasayana* (rejuvenator) and *Shonita-sthapana* (haemostatic and blood enhancer), *Lavanga* as *Shoolanashaka* (analgesic), *Ela* as *Kandu-nashaka* (anti-pruritic), *Tvak* as *Vrana-shodhaka* (wound purifier) and *Vrana-ropaka* (wound healer), *Tejapatra* as *Vatakapha-nashaka*, *Nagakesara* as *Kandughna* (anti-pruritic) and *Rakta-stambhak* (haemostatic), *Priyangu* as *Shonita-sthapana* (haemostatic and blood enhancer) and *Sandhaniya* (property of repairing and healing), *Haritaki* as *Tridosha-nashaka*, *Rasayana* (rejuvenator) and *Vrana-ropaka* (wound healer), *Vibhitaki* as *Kriminashaka* (anti-microbial), *Amalaki* as *Rasayana* (rejuvenator), *Tridosha-nashaka* and *Shonita-sthapana* (haemostatic and blood enhancer) *Dravya*^[7]. *Abhraka Bhasma* acts as *Rasayana* (rejuvenator), *Tridosha-nashaka* and *Sarvaroga-hara*. *Loha Bhasma* is *Uttama Rasayana* (great rejuvenator), *Krimi-hara* (anti-microbial), *Shotha-hara* (anti-inflammatory), *Balya* (property of strengthening) and *Deepana* (improves metabolism and digestion)^[8].

Lakshadi Guggul^[9]

It is referred from *Bhaisajya Ratnavali*. The drug is mentioned for fractures, bone diseases, injuries and pain related to them, *Dhatu-ksheenta* (debility) and *Vata* disorders. This signifies its action in fibrous and bone healing. Here we can consider its fibrous healing action. The main contents are *Laksha*, *Asthishrinkhala*, *Arjuna-chhal*, *Ashwagandha*, *Nagabala-mulatvaka* and *Guggul*. All of them possess *Ropana* (healing) and *Rasayana* (rejuvenator) properties.

Laksha acts as *Uttama Vrana-ropaka* (best for fibrous healing), *Asthishrinkhala* (*Hadjoda*) as *Asthi-sandhankara* (best for fibrous and bone repairing), *Arjuna-chhal* as *Vrana-hara* (wound healer), *Ashwagandha* as *Rasayana* (rejuvenator), *Brimhana* (property of nourishment) and *Balya* (property of strengthening), *Nagabala-mulatwak* as *Uttama Rasayana* (great rejuvenator), *Guggul* as *Bhagna-sandhankrita* (property of fracture healing), *Rasayana* (rejuvenator), *Deepana* (improves metabolism and digestion), *Balya* (property of strengthening), *Kleda-hara* (removes putrefaction), *Krimi-nashaka* (anti-microbial) and *Sarvadosha-hara Dravya*^[7].

Mahayograj Guggul^[10]

The preparation is mentioned in *Sharangdhara Samhita*. It has been recommended for its *Tridosha-hara* action, *Mandagni-Aruchi-nashaka* (improves metabolism and digestion), *Shoatha-hara* (anti-inflammatory), *Shoola-prashamana* (analgesic) and *Rasayana* (rejuvenator) properties. It contains *Shunthi*, *Pippali*, *Pippali-mula*, *Chavya*, *Chitraka-mula*, *Ghritha Bhrishtha Hingu*, *Ajmoda*, *Peeta Sarshapa*, *Jeeraka-dvaya*, *Renuka*, *Indrayava*, *Patha*, *Vayavidanga*, *Gajapippali*, *Kutki*, *Ativisha*, *Bharangi-mula*, *Murva*, *Vacha*, *Haritaki*, *Vibhitaki*, *Amalaki*, *Vanga Bhasma*, *Rajata Bhasma*, *Naga Bhasma*, *Loha Bhasma*, *Abhraka Bhasma*, *Mandoora Bhasma*, *Rasa Sindoor*, *Guggul* and *Ghritha*.

Shunthi, *Pippali*, *Pippali-mula*, *Chavya*, *Chitraka-mula* acts as *Deepana* (improves metabolism and digestion), *Ghritha Bhrishtha Hingu* as *Shoola-hara* (analgesic), *Ajmoda* as *Kaphavata-nashaka* and *Krimi-hara* (anti-microbial), *Peeta Sarshapa* as *Kandu-hara* (anti-pruritic) and *Krimi-hara* (anti-microbial and vermifuge), *Jeeraka-dvaya* as *Balya* (property of strengthening), *Renuka* as *Kandu-nashaka* (anti-pruritic), *Indrayava* as *Shonita-sthapana* (haemostatic and blood enhancer) and *Shoola-hara* (analgesic), *Patha* as *Shoola-hara* (analgesic), *Kandu-hara* (anti-pruritic), *Vrana-ropaka* (wound healer) and *Krimi-hara* (anti-microbial), *Vayavidanga*, *Gajapippali*, *Kutki* and *Ativisha* as *Krimi-hara* (anti-microbial), *Bharangi-mula* as *Raktadosha-hara* and *Shoatha-hara* (anti-inflammatory), *Murva* as *Kandu-hara* (anti-pruritic), *Vacha* as *Krimi-hara* (anti-microbial), *Shoola-ghna*

(analgesic)^[7]. *Vanga Bhasma* acts as *Kapha-hara*, *Krimi-hara* (anti-microbial), *Deepana* (improves metabolism and digestion) and *Vrana-ropaka* (wound healer), *Rajata Bhasma* as *Deepana* (improves metabolism and digestion) and *Sarvaroga-hara*, *Naga Bhasma* as *Deepana* (improves metabolism and digestion), *Vatakapha-nashaka*, *Vrana-ropaka* (wound healer) and *Balya* (property of strengthening), *Loha Bhasma* as *Uttama Rasayana* (great rejuvenator), *Krimi-hara* (anti-microbial), *Shoatha-hara* (anti-inflammatory), *Balya* (property of strengthening) and *Deepana* (improves metabolism and digestion), *Abhraka Bhasma* as *Rasayana* (rejuvenator), *Tridosha-nashaka* and *Sarvaroga-hara*, *Mandoora Bhasma* (same as *Loha Bhasma*), *Rasa Sindoor* as *Tridosha-nashaka*, *Shoatha-hara* (anti-inflammatory), *Shoola-hara* (analgesic), *Uttama Vrana-ropaka* (great wound healer) and *Rasayana* (rejuvenator)^[8]. *Guggul* acts as *Bhagna-sandhankrita* (property of fracture healing), *Rasayana* (rejuvenator), *Deepana* (improves metabolism and digestion), *Balya* (property of strengthening), *Kleda-hara* (removes putrefaction), *Krimi-nashaka* (anti-microbial) and *Sarvadosha-hara Dravya*^[7]. *Ghritha* (cow ghee) has lipophilic action, so it helps in ion transportation to a target organ and facilitates entry of drug in to cell and its delivery to mitochondria, microsome and nuclear membrane. Also, it helps in restoring the normal texture of the structure^[11].

Gandha Taila^[12]

This formulation is mentioned in *Ashtanga Hridayam Uttarsthana* 27/36-41 in *Bhagna Pratishedha Adhyaya*.

This is mentioned as *Uttama Asthi-sthairyakara* and *Vatapitta-nashaka*. It can be administered through oral route, nasal route and can be applied locally. The ingredients are *Yashti*, *Nalada*, *Valaka*, *Manjishtha*, *Nakha*, *Mishi*, *Mustaka*, *Kushtha*, *Bala*, *Atibala*, *Mahabala*, *Aguru*, *Kumkuma*, *Chandana*, *Sariva*, *Sarala*, *Sarjarasa*, *Devdaru*, *Padmakadi Gana*, *Eladi Gana*, *Shaileya*, *Rasna*, *Shalparni*, *Kaseruka*, *Kalanusari*, *Nata*, *Patra*, *Lodhra*, *Kakoli* (*Ksheershukla*), *Durva*, *Godugdha* and *Krishna-Tila Taila*.

Yashti acts as *Uttama Ropana* (best for wound healing), *Rasayana* (rejuvenator) and *Shonita-sthapana* (haemostatic and blood enhancer), *Nalada* as *Raktaprakopa-nashaka* and *Vranapahama* (wound healer), *Manjishtha* as *Shonita-sthapana* (haemostatic and blood enhancer), *Nakha* as *Vrana-hara* (wound healer), *Mishi* as *Shoola-hara* (analgesic), *Vrana-ropaka* (wound healer) and *Krimi-hara* (anti-microbial), *Mustaka* as *Jantu-hara* (anti-microbial and vermifuge) and *Kaphapittarakta-nashaka*, *Kushtha* as *Lekhana* (scrapping) and *Kandu-hara*, *Bala*, *Atibala*, *Mahabala* as *Balya* (property of strengthening), *Vrana-ropaka* (wound healer) and *Raktavikara-nashaka*, *Aguru* as

Karna Roga-nashaka, *Kumkuma* as *Vrana-nashaka* (wound healer) and *Krimi-hara* (anti-microbial), *Chandana* as *Vrana-hara* (wound healer), *Sariva* as *Rakta-stambhaka* (haemostatic), *Sarala* as *Vrana-hara* (wound healer), *Sarjarasa* as *Shoola-hara* (analgesic), *Vrana-ropaka* (wound healer) and *Bhagna-sandhankara* (property of fracture healing), *Devdaru* as *Kanduhara* (anti-pruritic) and *Shotha-hara* (anti-inflammatory), *Padmakadi Gana* as *Kushtha-Vrana-Daha-Raktapitta-nashaka*, *Eladi Gana* as *Kaphavishanashaka* and *Kandu-hara* (anti-pruritic), *Shaileya* as *Kandu-hara* (anti-pruritic) and *Daha-shamaka* (relieves burning sensation), *Rasna* as *Vata-hara*, *Shalparni* as *Rasayana* (rejuvenator) and *Krimi-hara* (anti-microbial), *Kaseruka* as *Pitta-shonita-dahaghna*, *Kalanusari* as *Krimi-hara* (anti-microbial), *Patra* as *Vatakapha-nashaka*, *Lodhra* as *Shotha-hara* (anti-inflammatory) and *Raktavikara-nashaka*, *Kakoli* (*Ksheershukla*) as *Rakta-pitta-daha-nashaka* (relieves burning sensation), *Durva* as *Rakta-stambhaka* (haemostatic) and *Pittarakta-nashaka dravya*. *Godughda* acts as *Vata-pitta-rakta-nashaka* and *Sarvaroga-nashaka*. *Tila Taila* acts as *Balya* (strengthening), *Brimhana* (nourishment), *Lekhana* (property of scrapping), *Deepana* (improves metabolism and digestion), *Vrana-hara* (wound healer), *Karnashoola-nashaka* (relieves earache)^[7].

Vatari Churna

It is a patent formulation of Divya pharmacy. It contains *Shunthi*, *Vidhara*, *Kutki*, *Ashwagandha*, *Methi* and *Suranjana*.

Shunthi acts as *Kaphavata-hara*, *Vidhara* as *Shotha-hara* (anti-inflammatory), *Kutki* as *Krimi-hara* (anti-microbial), *Ashwagandha* as *Rasayana* (rejuvenator), *Brimhana* (property of nourishment) and *Balya* (property of strengthening), *Methi* as *Kapha-nashaka* and *Suranjana* as *Vatarakta-nashaka Dravya*^[7].

Ashwagandha Churna

It has *Rasayana* (rejuvenation), *Brimhana* (nourishment) and *Balya* (strengthening) properties^[7].

Mulethi Churna

Mulethi is *Uttama Ropana* (best for wound healing), *Rasayana* (rejuvenator) and *Shonita-sthapana* (haemostatic and blood enhancer) in properties^[7].

These medications are rich in *Shodhana* (purification), *Ropana* (wound healing), *Krimi-hara* (anti-microbial), *Shotha-hara* (anti-inflammatory), *Rasayana* (rejuvenator), *Kandu-hara* (anti-pruritic) and *Shonita-sthapana* (haemostatic and blood enhancer) properties. They help in the thorough healing of *Agantuja Vrana*. The healing effect resulted from the synergistic impact of various substances working together.

So, all these properties enhance the health of tympanic membrane and lining of EAC chiefly at cellular level and reduce keratinization, therefore, maintaining healthy cell cycle. They reduce symptoms such as itching, traumatic derangement of lining and unctuousness, restoring them to normal texture for both ear canal and tympanic membrane.

Rapid healing is seen in patients with small perforation and early treatment. Here in this case, the patient presented after 1 month of trauma and the size of perforation was big. So, the regeneration of the tissue was somehow slower than expected. But the medications were prompt, thus leading to complete healing in 2 months.

The *Rasayana* (rejuvenating), *Brimhana* (nourishment) and *Balya* (strengthening) properties of *Dravyas* imparted nourishment and strength and eventually, promoted the rejuvenation of all three layers of the membrane, and therefore, it encouraged the fibroblastic response and granulation in the perforated edges which is essential for repairing of wound. *Vrana-ropaka* (wound healing), *Vrana-shodhaka* (wound purification), *Sandhaniya* (healing) and *Bhagna-sandhankara* (fibrous healing) property stimulated the process of healing and repairing, thus lead to increased vascularity of the tympanic membrane. *Shotha-hara* (anti-inflammatory) property reduced *Shotha* (inflammation) caused by the trauma, and *Shoola-hara* (analgesic) property lowered the pain. The *Krimi-hara* (anti-microbial) property prevented and cured the potential infection which may have complicated the disease. The *Kanduhara* (anti-pruritic) property treated the itching sensation which the patient came with. The *Shonita-sthapana* (haemostatic and blood enhancer) and *Rakta-stambhaka* (haemostatic) properties stopped bleeding points created due to traumatic rupture. The *Deepana* property improved the digestion, thus eased the uptake of other *Dravyas*. It also improved metabolism even at molecular level resulting in complete healing of the perforation and subsided the associated symptoms.

CONCLUSION

This case is based on the management of patient on an OPD basis who was diagnosed with traumatic perforation and was kept on the line of treatment of *Agantuja Vrana*. Internal medications which were easy to administer and easily available, were prescribed. The *Vrana-ropaka*, *Shotha-hara* (anti-inflammatory) and *Rasayana* (rejuvenating) properties were found to be very useful in the management of traumatic perforation. No other intervention was introduced during the course of treatment. The current study provides a way for more clinical trials on a larger scale to evaluate the effect of *Sarivadi Vati*, *Mahayograj Guggul*, *Lakshadi Guggul*, *Gandha Taila* and combination of *Vatari*, *Ashwagandha* and *Mulethi*

Churna on traumatic perforation. This will provide a smoother way to treat the condition without any instrumental intervention and topical therapy.

REFERENCES

1. Lou ZC, Lou ZH, Zhang QP. Traumatic tympanic membrane perforations: A study of etiology and factors affecting outcome. *Am J Otolaryngol*. 2012; 33: 549-55.
2. Ambikadatta Shastri, Sushruta Samhita Purvardha, Sutrasthana 22/4. 200112th Varanasi, Chaukhamba Sanskrit Sansthana: 95
3. Yilmaz MS, Sahin E, Kaymaz R, et al. Histological Study of The Healing of Traumatic Tympanic Membrane Perforation After Vivosorb and Epifilm Application. *Ear, Nose & Throat Journal*. 2021; 100(2): 90-96. doi:10.1177/0145561319854320
4. Chaudhary Shraddha, Dharmendra B, Kasambi D. Management for traumatic tympanic membrane perforation: A case series. *Journal of Indian System of Medicine*. 2023; 11(2): p 102-107.
5. Sogebi OA, Oyewole EA, Mabifah TO. Traumatic tympanic membrane perforations: characteristics and factors affecting outcome. *Ghana Med J*. 2018 Mar; 52(1): 34-40. doi: 10.4314/gmj.v52i1.7. PMID: 30013259; PMCID: PMC6026949.
6. Prof. Mishr Sidhinandana, Kaviraj Shri-Govind-Das-Sen-virachita Bhaisajya Ratnavali. *Karnarogadhikara* 62/69-74. 2016. Chaukhambha Surbharti Prakshan, Varanasi.
7. Dr. Chunekar KC, Dr. Pandey GS, Bhavaprakasha Nighantu. 2002. Chaukhambha Bharti Academy, Varanasi.
8. Acharya Mishr Sidhinandana, Bhasma-Vigyan. 2021. Chaukhambha Orientalia, Varanasi.
9. Prof. Mishr Sidhinandana, Kaviraj Shri-Govind-Das-Sen-virachita Bhaisajya Ratnavali. *Bhagnadhikara* 49/12-13. 2016. Chaukhambha Surbharti Prakshan, Varanasi.
10. Shri Vibhutibhushan Soor. Shri Sharangdh aracharya pranita Sharangdhara Samhita *Madhyama Khanda* 7/ 56-60. Pandit Pustakalya, Kashi. 1950.
11. Chaudhary Shraddha, Dharmendra B, Kasambi D. Management for traumatic tympanic membrane perforation: A case series. *Journal of Indian System of Medicine*. 2023; 11(2): p 102-107.
12. Dr.Tripathi Brahmanand, Ashtanga Hridayam *Uttarsthana* 27/36-41. Chaukhambha Sanskrit Pratishtan, Delhi.

Cite this article as:

Pahwa Preeti, Saini Jasmeen, Vinaik Ashu. Management of Traumatic Perforation of Tympanic Membrane Through Ayurveda. *International Journal of Ayurveda and Pharma Research*. 2024;12(5):116-111.

<https://doi.org/10.47070/ijapr.v12i5.3218>

Source of support: Nil, Conflict of interest: None Declared

*Address for correspondence

Dr. Pahwa Preeti

Associate Professor,
PG Department of Shalakyata-Tantra,
Patanjali Bhartiya Ayurvigyan
Evam Anusandhan Sansthan,
Haridwar, Uttarakhand.
Email: drpreeti25@gmail.com

Disclaimer: IJAPR is solely owned by Mahadev Publications - dedicated to publish quality research, while every effort has been taken to verify the accuracy of the content published in our Journal. IJAPR cannot accept any responsibility or liability for the articles content which are published. The views expressed in articles by our contributing authors are not necessarily those of IJAPR editor or editorial board members.